



Chapter 9

The Hip and pelvic Joint

Manual of Structural Kinesiology

R.T. Floyd, EdD, ATC, CSCS

© 2007 McGraw-Hill Higher Education. All rights reserved.

10-1

The Hip Joint and Pelvic Girdle

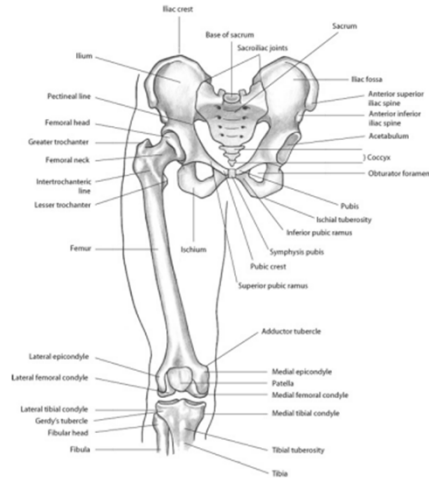
- **Hip joint (acetabular femoral)**
 - relatively stable due to
 - bony architecture
 - strong ligaments
 - large supportive muscles
 - functions in weight bearing & locomotion
 - enhanced significantly by its wide range of motion
 - ability to run, cross-over cut, side-step cut, jump, & many other directional changes

© 2007 McGraw-Hill Higher Education. All rights reserved.

9-2

Bones

- **Ball & socket joint**
 - Head of femur connecting with acetabulum of pelvic girdle
 - Pelvic girdle
 - right & left pelvic bone joined together posteriorly by sacrum
 - pelvic bones are ilium, ischium, & pubis
 - Femur
 - longest bone in body

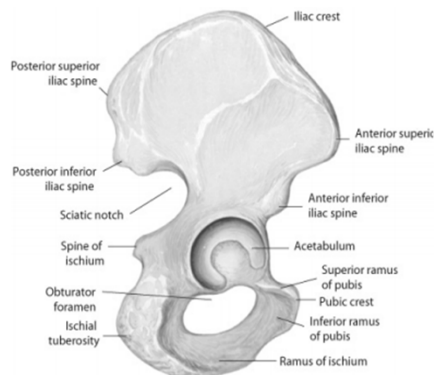


© 2007 McGraw-Hill Higher Education. All rights reserved.

9-3

Bones

- Sacrum
 - extension of spinal column with 5 fused vertebrae
 - extending inferiorly is the coccyx
- Pelvic bone - divided into 3 areas
 - Upper two fifths = ilium
 - Posterior & lower two fifths = ischium
 - Anterior & lower one fifth = pubis

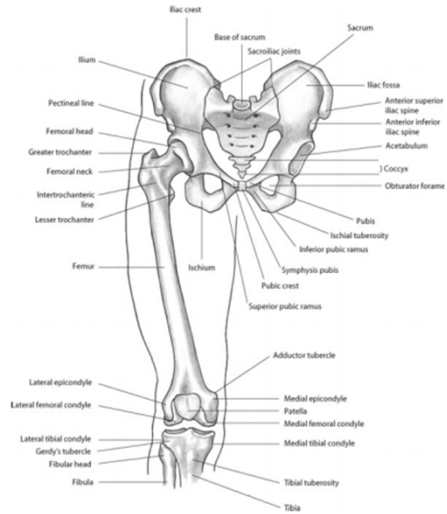


© 2007 McGraw-Hill Higher Education. All rights reserved.

9-4

Bones

- **Bony landmarks**
 - Anterior pelvis - origin for hip flexors
 - tensor fasciae latae - anterior iliac crest
 - sartorius - anterior superior iliac spine
 - rectus femoris - anterior inferior iliac spine

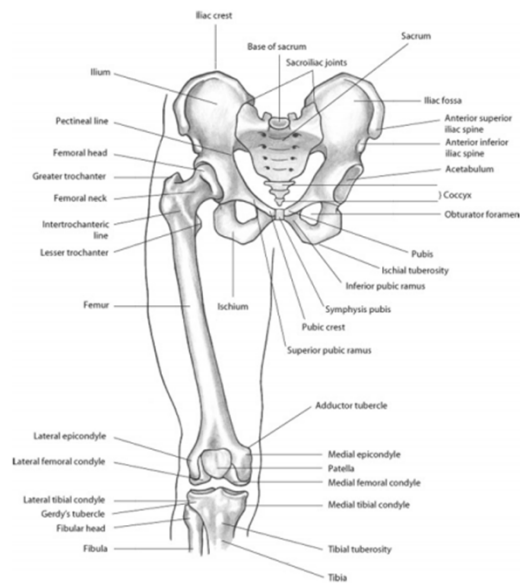


© 2007 McGraw-Hill Higher Education. All rights reserved.

9-5

Bones

- **Bony landmarks**
 - Lateral pelvis - origin for hip abductors
 - gluteus medius & minimus - just below iliac crest

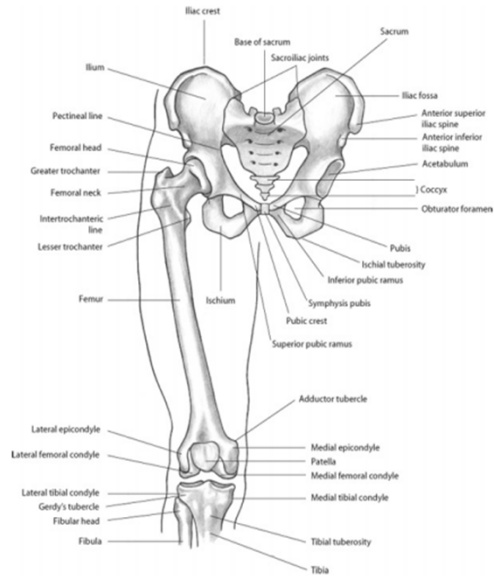


© 2007 McGraw-Hill Higher Education. All rights reserved.

9-6

Bones

- Bony landmarks
 - Medially - origin for hip adductors
 - adductor magnus, adductor longus, adductor brevis, pectineus, & gracilis - pubis & its inferior ramus

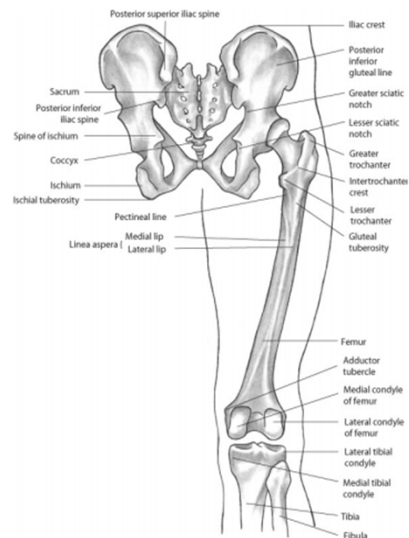


© 2007 McGraw-Hill Higher Education. All rights reserved.

9-7

Bones

- Bony landmarks
 - Posteriorly – origin for hip extensors
 - gluteus maximus - posterior iliac crest & posterior sacrum & coccyx
 - Posteroinferiorly - origin for hip extensors
 - hamstrings - ischial tuberosity

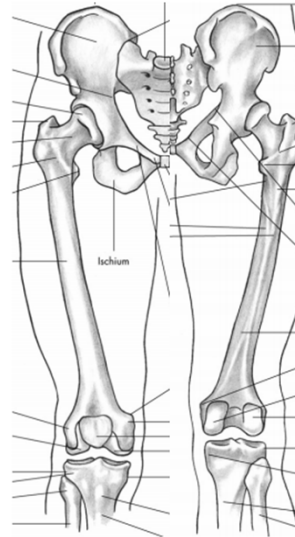


© 2007 McGraw-Hill Higher Education. All rights reserved.

9-8

Bones

- Bony landmarks
 - Proximal thigh - insertion for short muscles of hip
 - gluteal muscles & most of the six deep external rotators - greater trochanter
 - iliopsoas - lesser trochanter
 - Proximal thigh - origin for 3 knee extensors
 - three vasti muscles of quadriceps – anteriorly
 - hip adductors - linea aspera



© 2007 McGraw-Hill Higher Education. All rights reserved.

9-9

Bones

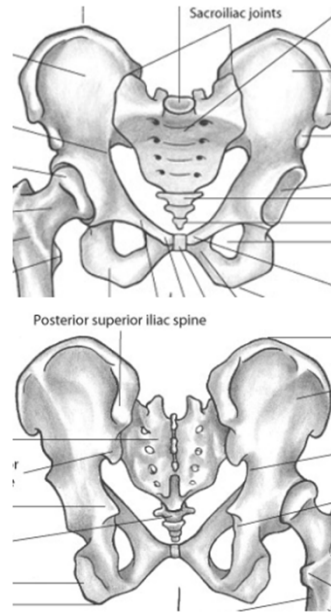
- Bony landmarks
 - Patella – insertion for all 4 quadriceps muscles
 - Proximal tibia or fibula – insertion for remainder of hip muscles
 - sartorius, gracilis, & semitendinosus - upper anteromedial tibial surface just below medial condyle after crossing knee posteromedially
 - semimembranosus - posteromedially on medial tibial condyle

© 2007 McGraw-Hill Higher Education. All rights reserved.

9-10

Joints

- Anteriorly
 - Two pelvic bones join to form symphysis pubis, amphiarthrodial
- Posteriorly
 - Sacrum is between the 2 pelvic bones & forms the sacroiliac joints
 - Strong ligaments unite these bones to form rigid, slightly movable joints



© 2007 McGraw-Hill Higher Education. All rights reserved.

9-11

Joints

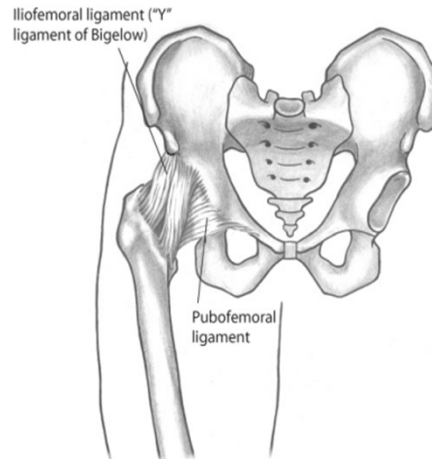
- Acetabulofemoral joint - most mobile joints of body (except glenohumeral)
 - Multiaxial arrangement
 - Bony architecture provides stability
 - relatively few hip joint subluxations & dislocations
 - Enarthrodial-type joint
 - Femoral head inserting into acetabulum
 - Reinforced by extremely strong & dense ligamentous capsule, especially anteriorly

© 2007 McGraw-Hill Higher Education. All rights reserved.

9-12

Joints

- Acetabulofemoral joint
 - Iliofemoral or Y ligament – located anteriorly, prevents hyperextension
 - Pubofemoral ligament - located anteromedially & inferiorly, limits excessive extension & abduction

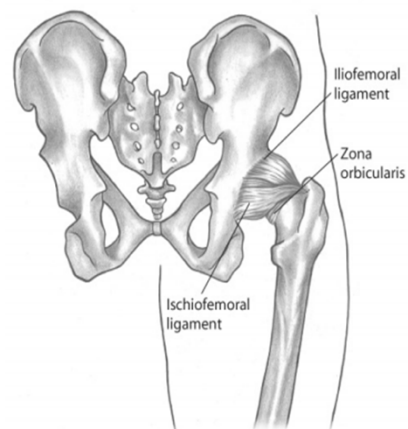


© 2007 McGraw-Hill Higher Education. All rights reserved.

9-13

Joints

- Acetabulofemoral joint
 - Teres ligament - attaches from deep in acetabulum to a depression in femoral head, slightly limits adduction
 - Ischiofemoral ligament – located posteriorly, extends from ischium to trochanteric fossa of femur, limits internal rotation

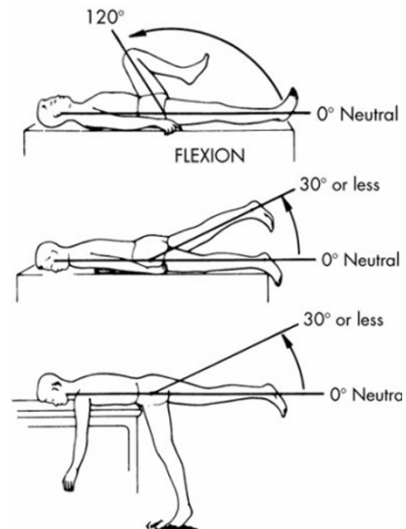


© 2007 McGraw-Hill Higher Education. All rights reserved.

9-14

Joints

- Some disagreement about exact possible range of each movement in hip joint
 - 0 to 130 degrees of flexion
 - 0 to 30 degrees of extension

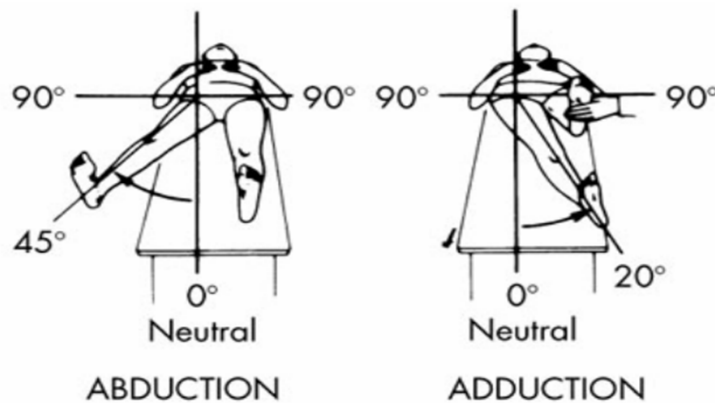


© 2007 McGraw-Hill Higher Education. All rights reserved.

9-15

Joints

- 0 to 35 degrees of abduction
- 0 to 30 degrees of adduction

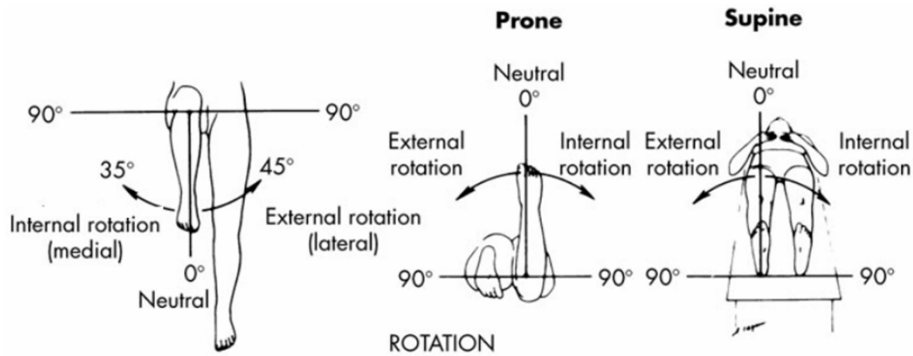


© 2007 McGraw-Hill Higher Education. All rights reserved.

9-16

Joints

- 0 to 45 degrees of internal rotation
- 0 to 50 degrees of external rotation



© 2007 McGraw-Hill Higher Education. All rights reserved.

9-17

Joints

Motions accompanying pelvic rotation

Pelvic Rotation	Lumbar Spine Motion	Right Hip Motion	Left Hip Motion
Anterior rotation	Extension	Flexion	Flexion
Posterior rotation	Flexion	Extension	Extension
Right lateral rotation	Right lateral flexion	Adduction	Abduction
Left lateral rotation	Left lateral flexion	Abduction	Adduction
Right transverse rotation	Left transverse rotation	Internal rotation	External rotation
Left transverse rotation	Right transverse rotation	External rotation	Internal rotation

© 2007 McGraw-Hill Higher Education. All rights reserved.

9-18

Movements

- Anterior & posterior pelvic rotation
 - sagittal or anteroposterior plane
- Right & left lateral rotation
 - lateral or frontal plane
- Right transverse (clockwise) rotation & left transverse (counterclockwise) rotation
 - horizontal or transverse plane of motion

© 2007 McGraw-Hill Higher Education. All rights reserved.


9-19

Movements

- Hip flexion
 - movement of femur straight anteriorly toward pelvis
- Hip extension
 - movement of the femur straight posteriorly away from the pelvis; sometimes referred to as hyperextension



Flexion
A



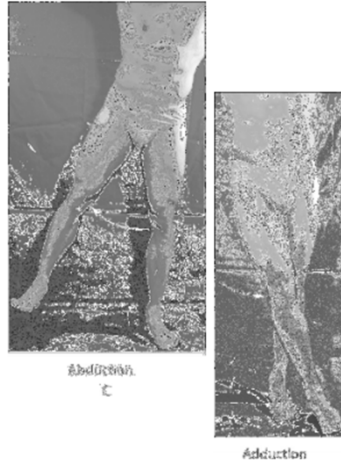Extension

© 2007 McGraw-Hill Higher Education. All rights reserved.

9-20

Movements

- Hip abduction
 - movement of femur laterally to side away from midline
- Hip adduction
 - movement of femur medially toward midline

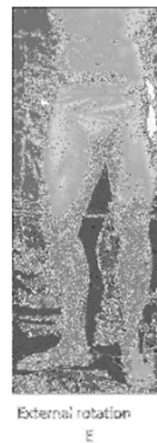


© 2007 McGraw-Hill Higher Education. All rights reserved.

9-21

Movements

- Hip external rotation
 - rotary movement of femur laterally around its longitudinal axis away from midline; lateral rotation
- Hip internal rotation
 - rotary movement of femur medially around its longitudinal axis toward to midline; medial rotation




© 2007 McGraw-Hill Higher Education. All rights reserved.

9-22

Movements

- Hip diagonal abduction
 - movement of femur in a diagonal plane away from midline of body
- Hip diagonal adduction
 - movement of femur in a diagonal plane toward midline of body

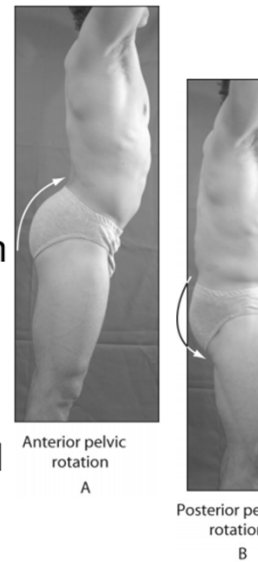

© 2007 McGraw-Hill Higher Education. All rights reserved.

9-23

Movements

- Anterior pelvic rotation
 - anterior movement of upper pelvis; iliac crest tilts forward in a sagittal plane; anterior tilt
- Posterior pelvic rotation
 - posterior movement of upper pelvis; iliac crest tilts backward in a sagittal plane; posterior tilt

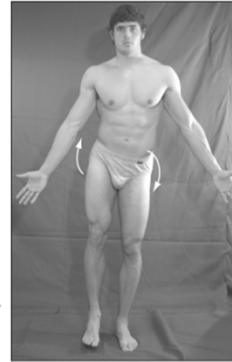

© 2007 McGraw-Hill Higher Education. All rights reserved.

9-24

Movements

- **Left lateral pelvic rotation**
 - in frontal plane left pelvis moves inferiorly in relation to right pelvis; either left pelvis rotates downward or right pelvis rotates upward; left lateral tilt
- **Right lateral pelvic rotation**
 - in frontal plane right pelvis moves inferiorly in relation to left pelvis; either right pelvis rotates downward or left pelvis rotates upward: right lateral tilt



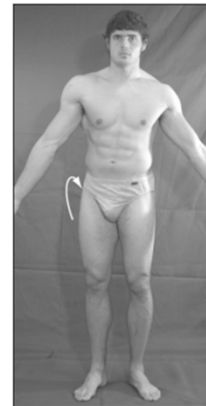Left lateral pelvic rotation
C

© 2007 McGraw-Hill Higher Education. All rights reserved.

9-25

Movements

- **Left transverse pelvic rotation**
 - in horizontal plane pelvis rotates to body's left; right iliac crest moves anteriorly in relation to left iliac crest, which moves posteriorly
- **Right transverse pelvic rotation**
 - in horizontal plane pelvis rotates to body's right; left iliac crest moves anteriorly in relation to right iliac crest, which moves posteriorly



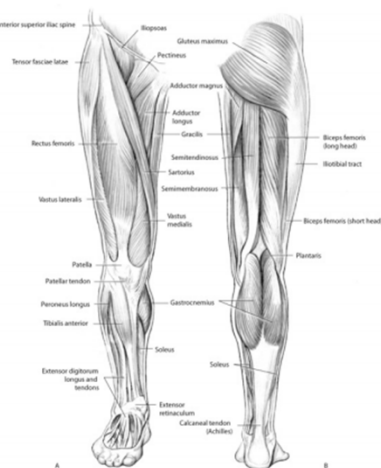
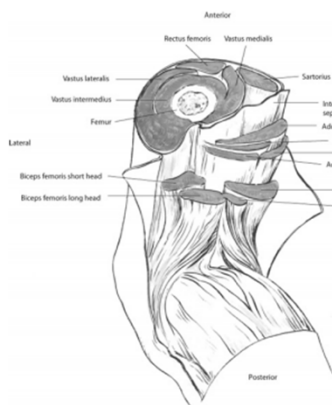
Right transverse pelvic rotation
D

© 2007 McGraw-Hill Higher Education. All rights reserved.

9-26

Muscles

- Seven two-joint muscles have one action at hip & another at knee

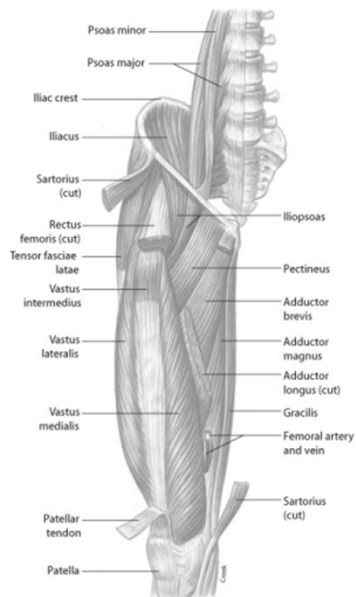


© 2007 McGraw-Hill Higher Education. All rights reserved.

9-27

Muscles

- Hip joint & pelvic girdle muscles
 - Anterior - primarily hip flexion
 - Iliopsoas
 - Pectineus
 - Rectus femoris
 - Sartorius



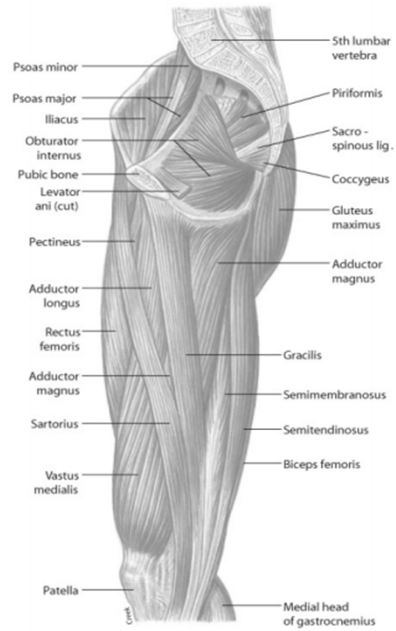© 2007 McGraw-Hill Higher Education. All rights reserved.

9-28

Muscles

– Medial - primarily hip adduction

- Adductor brevis
- Adductor longus
- Adductor magnus
- Gracilis



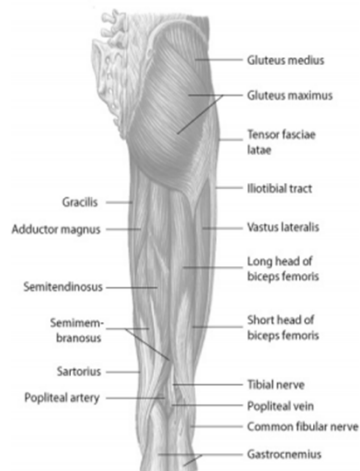
© 2007 McGraw-Hill Higher Education. All rights reserved.

9-29

Muscles

– Posterior - primarily hip extension

- Gluteus maximus
- Biceps femoris
- Semitendinosus
- Semimembranosus
- External rotators



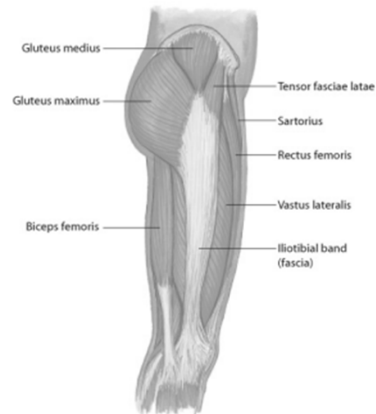© 2007 McGraw-Hill Higher Education. All rights reserved.

9-30

Muscles

– Lateral - primarily hip abduction

- Gluteus medius
- Gluteus minimus
- External rotators
- Tensor fasciae latae



© 2007 McGraw-Hill Higher Education. All rights reserved.

9-31

Muscles

- Pelvic muscles acting on hip joint
 - Iliac region - iliopsoas muscle flexes hip
 - Iliacus
 - Psoas major
 - Psoas minor

© 2007 McGraw-Hill Higher Education. All rights reserved.

9-32

Muscles

- Pelvic muscles acting on hip joint
 - Gluteal region - extend & rotate hip
 - Gluteus maximus
 - Gluteus medius
 - Gluteus minimi
 - Tensor fascia latae
 - Six deep external rotators - piriformis, obturator externus, obturator internus, gemellus superior, gemellus inferior, & quadratus femoris

Muscles

- Anterior compartment – primarily knee extensors
 - Rectus femoris
 - Vastus medialis
 - Vastus intermedius
 - Vastus lateralis
 - Sartorius
- Posterior compartment - hamstring group
 - Biceps femoris
 - Semitendinosus
 - Semimembranosus

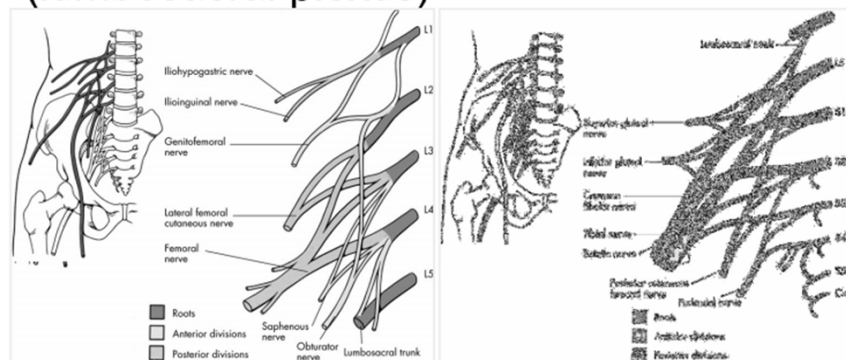
Muscles

– Medial compartment - primarily adductors

- Adductor brevis
- Adductor longus
- Adductor magnus
- Pectineus
- Gracilis

Nerves

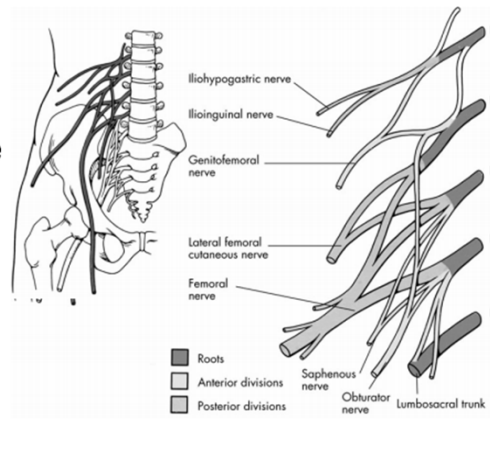
- All hip & pelvic girdle muscles - innervated from lumbar & sacral plexus (lumbosacral plexus)



Nerves

– Lumbar plexus - formed by anterior rami of spinal nerves L1 through L4 & some fibers from T12

- Lower abdomen and the anterior & medial portions of lower extremity



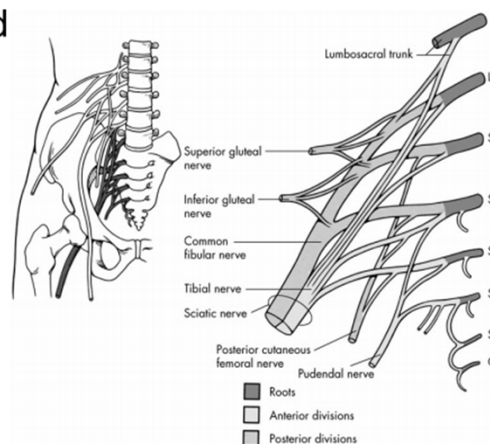
© 2007 McGraw-Hill Higher Education. All rights reserved.

9-37

Nerves

– Sacral plexus - formed by anterior rami of L4, L5, & S1 through S4

- Lower back, pelvis, perineum, posterior surface of thigh & leg, and dorsal & plantar surfaces of foot

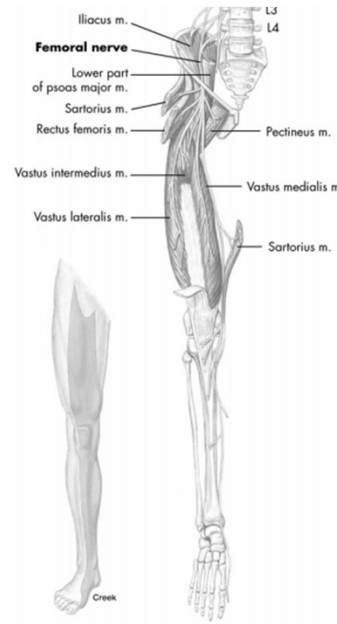


© 2007 McGraw-Hill Higher Education. All rights reserved.

9-38

Nerves

- Lumbar plexus - major nerves
 - Femoral n. - anterior muscles
 - Arises from posterior division of lumbar plexus
 - Iliopsoas
 - Rectus femoris
 - Vastus medialis
 - Vastus intermedius
 - Vastus lateralis
 - Pectineus
 - Sartorius
 - Sensation to anterior & lateral thigh and medial leg & foot

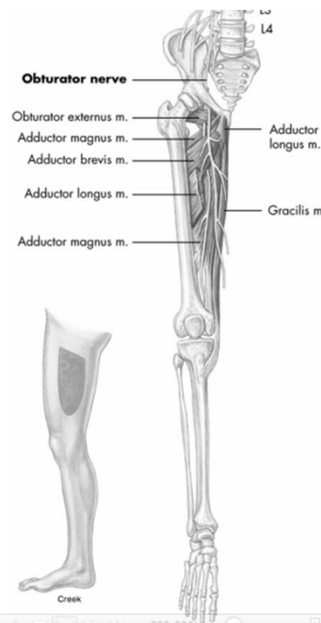


© 2007 McGraw-Hill Higher Education. All rights reserved.

9-39

Nerves

- Lumbar plexus - major nerves
 - Obturator nerve
 - Arises from anterior division of lumbar plexus
 - Adductor brevis
 - Adductor longus
 - Adductor magnus
 - Gracilis
 - Obturator externus
 - Sensation to medial thigh



© 2007 McGraw-Hill Higher Education. All rights reserved.

9-40

Nerves

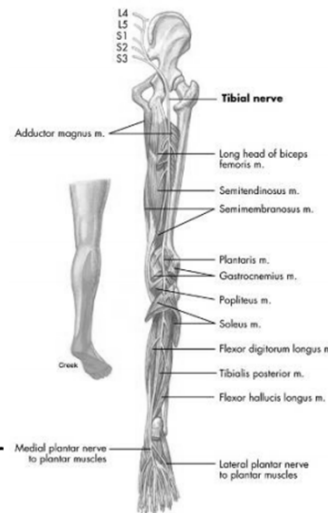- **Sacral plexus**
 - Superior gluteal nerve
 - arises from L4, L5, & S1 to innervate gluteus medius, gluteus minimus, & tensor fasciae latae
 - Inferior gluteal nerve
 - arises from L5, S1, & S2 to supply gluteus maximus
 - Branches from sacral plexus
 - piriformis (S1, S2), gemellus superior (L5, S1, S2), gemellus inferior & obturator internus (L4, L5, S1, S2), & quadratus femoris (L4, L5, S1)

© 2007 McGraw-Hill Higher Education. All rights reserved.

9-41

Nerves

- **Sacral plexus**
 - Sciatic nerve
 - tibial division
 - semitendinosus, semimembranosus, biceps femoris (long head) & adductor magnus
 - sensation for posterolateral lower leg & plantar aspect of foot
 - common peroneal (fibular) division
 - sensation to anterolateral lower leg & dorsum of foot



© 2007 McGraw-Hill Higher Education. All rights reserved.

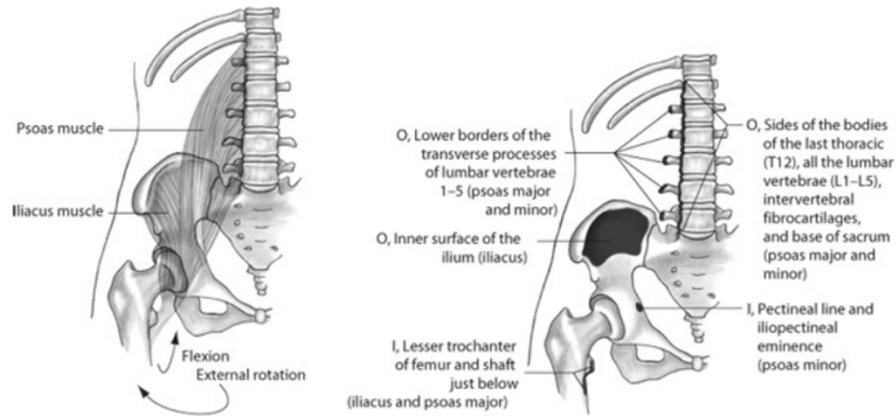
10-42

Iliopsoas Muscle

Flexion of hip

External rotation of femur

Transverse pelvic rotation contralaterally when ipsilateral femur is stabilized



© 2007 McGraw-Hill Higher Education. All rights reserved.

9-43

Sartorius Muscle

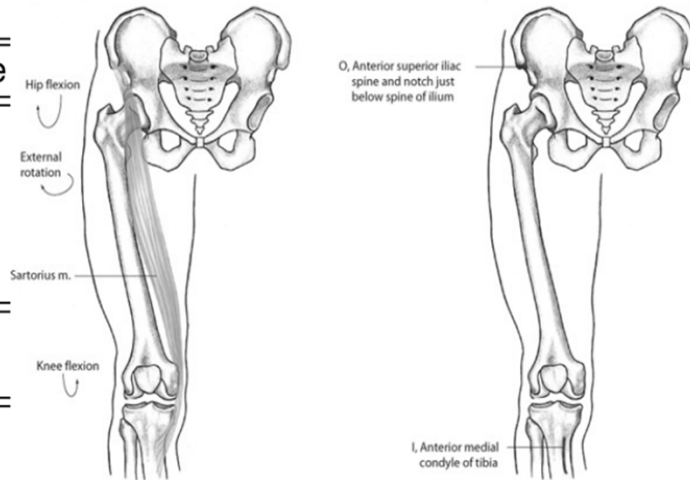
Flexion of hip

Flexion of knee

External rotation of thigh as it flexes hip & knee

Abduction of hip

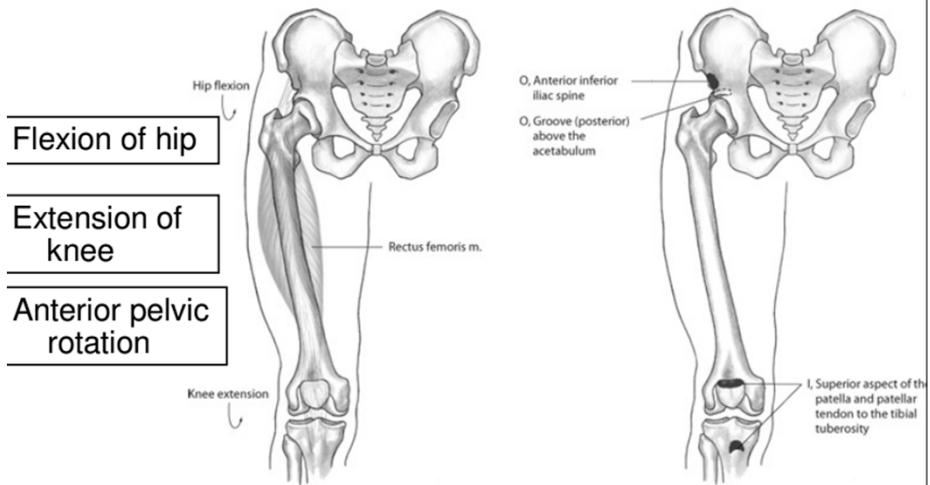
Anterior pelvic rotation



© 2007 McGraw-Hill Higher Education. All rights reserved.

9-44

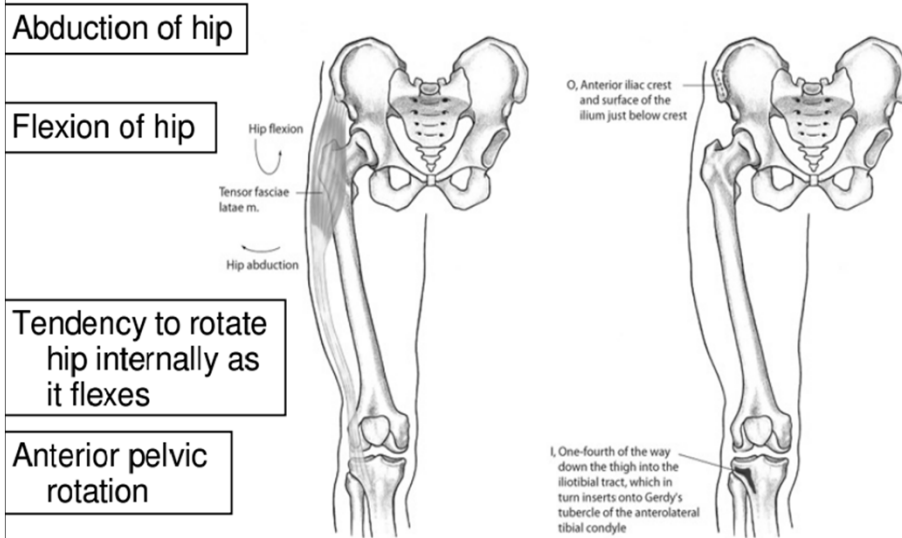
Rectus Femoris Muscle



© 2007 McGraw-Hill Higher Education. All rights reserved.

9-45

Tensor Fasciae Latae Muscle



© 2007 McGraw-Hill Higher Education. All rights reserved.

9-46

Gluteus Maximus Muscle

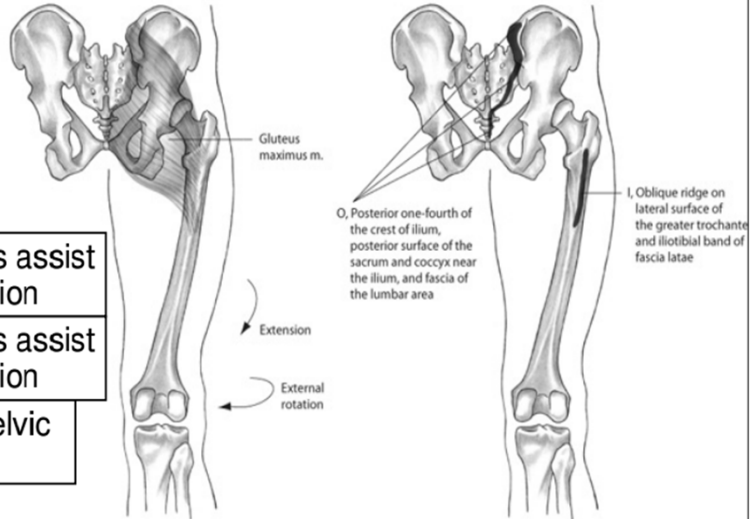
Extension of hip

External rotation of hip

Upper fibers assist in abduction

Lower fibers assist in adduction

Posterior pelvic rotation



© 2007 McGraw-Hill Higher Education. All rights reserved.

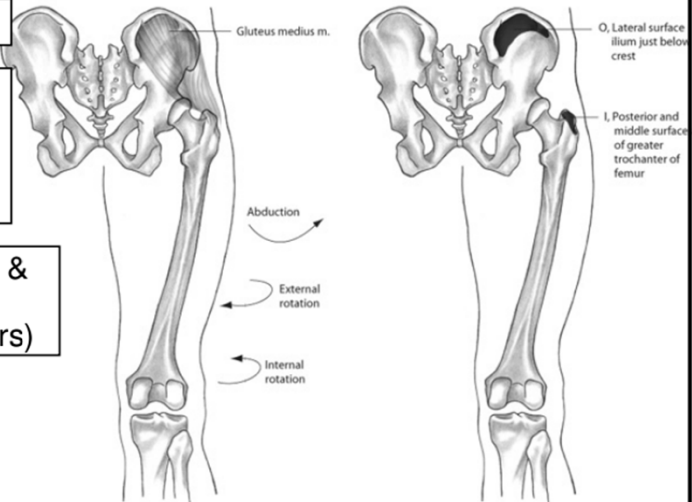
9-47

Gluteus Medius Muscle

Abduction of hip

Internal rotation & flexion (anterior fibers)

External rotation & extension (posterior fibers)



© 2007 McGraw-Hill Higher Education. All rights reserved.

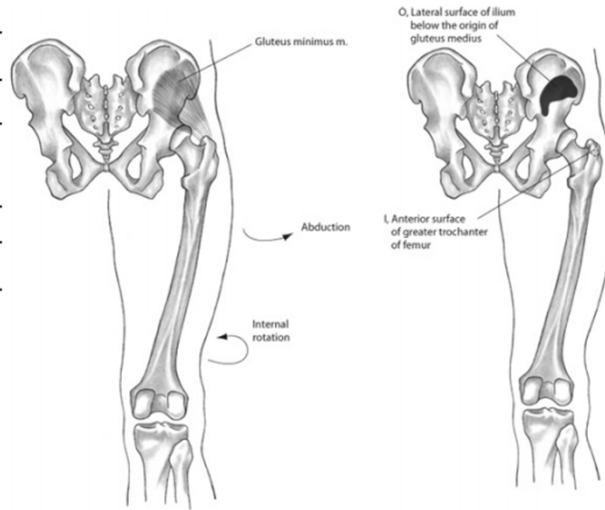
9-48

Gluteus Minimus Muscle

Abduction of hip

Internal rotation as femur abducts

Flexion of hip

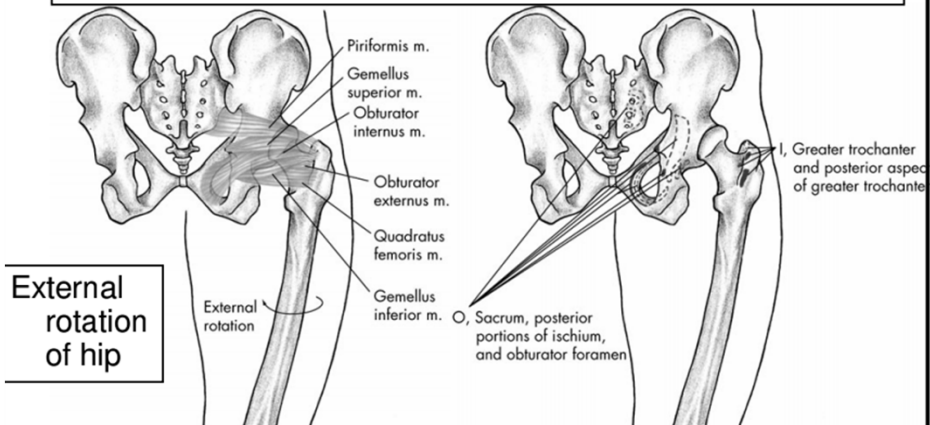


© 2007 McGraw-Hill Higher Education. All rights reserved.

9-49

Six Deep Lateral Rotator Muscles

Piriformis, Gemellus superior, Gemellus inferior, Obturator externus, Obturator internus, Quadratus femoris



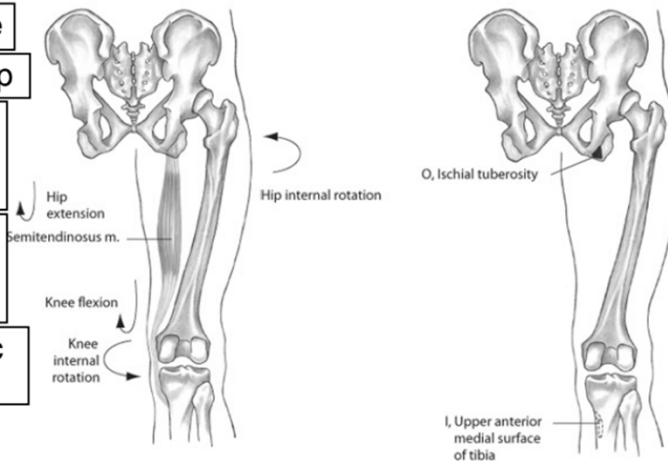
External rotation of hip

© 2007 McGraw-Hill Higher Education. All rights reserved.

9-50

Semitendinosus Muscle

- Flexion of knee
- Extension of hip
- Internal rotation of hip
- Internal rotation of flexed knee
- Posterior pelvic rotation

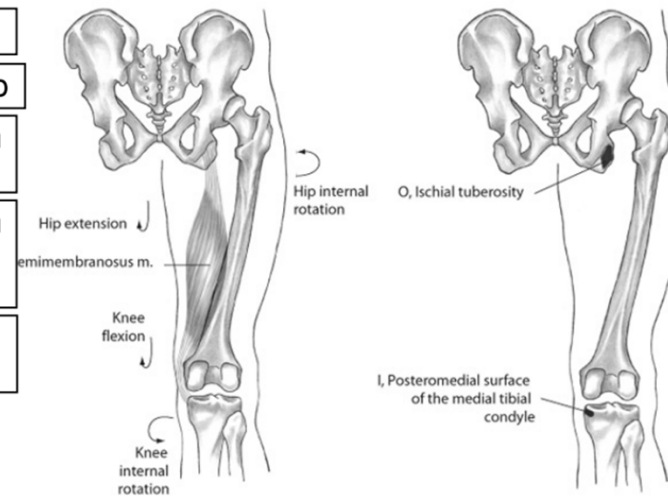


© 2007 McGraw-Hill Higher Education. All rights reserved.

9-51

Semimembranosus Muscle

- Flexion of knee
- Extension of hip
- Internal rotation of hip
- Internal rotation of flexed knee
- Posterior pelvic rotation



© 2007 McGraw-Hill Higher Education. All rights reserved.

9-52

Biceps Femoris Muscle

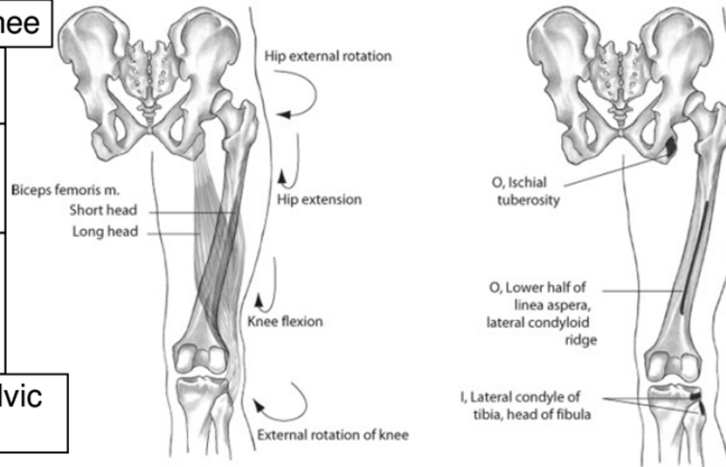
Flexion of knee

Extension of hip

External rotation of hip

External rotation of flexed knee

Posterior pelvic rotation



© 2007 McGraw-Hill Higher Education. All rights reserved.

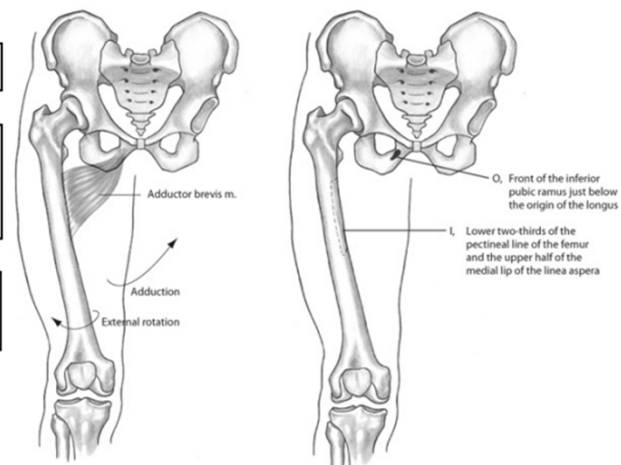
9-53

Adductor Brevis Muscle

Adduction of hip

External rotation as it adducts hip

Assists in flexion of hip



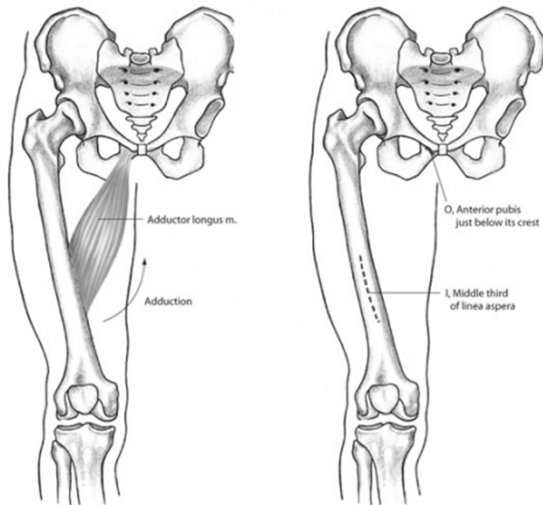
© 2007 McGraw-Hill Higher Education. All rights reserved.

9-54

Adductor Longus Muscle

Adduction of hip

Assists in flexion of hip



© 2007 McGraw-Hill Higher Education. All rights reserved.

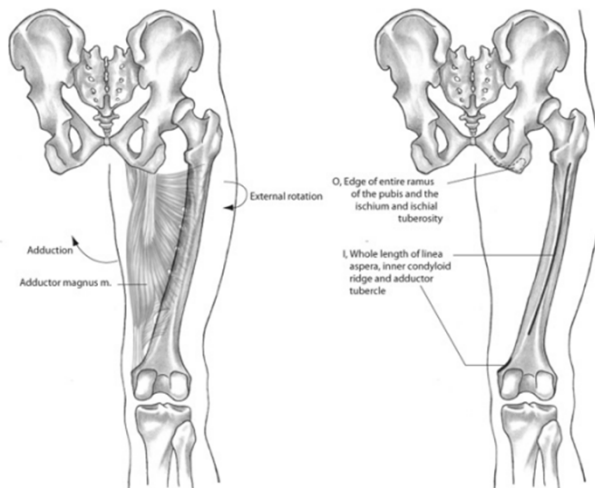
9-55

Adductor Magnus Muscle

Adduction of hip

External rotation as hip adducts

Extension of hip



© 2007 McGraw-Hill Higher Education. All rights reserved.

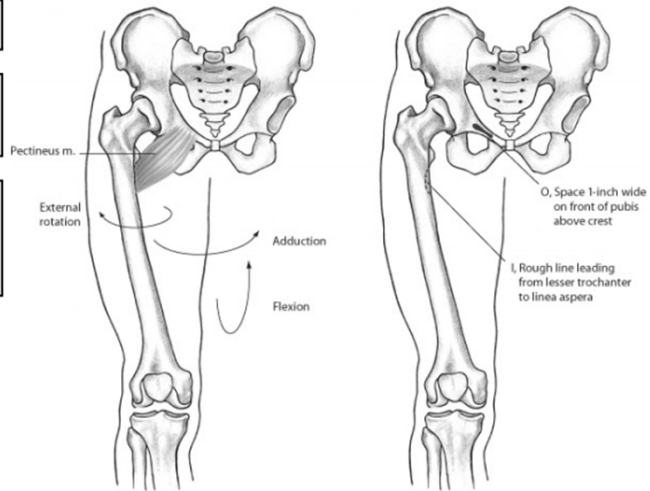
9-56

Pectineus Muscle

Flexion of hip

Adduction of hip

External rotation of hip



© 2007 McGraw-Hill Higher Education. All rights reserved.

9-57

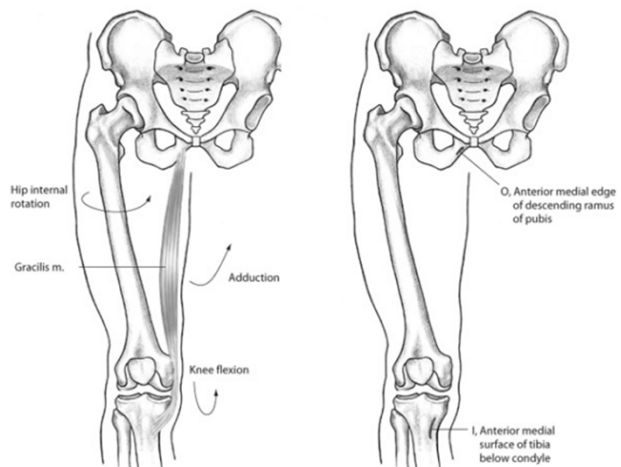
Gracilis Muscle

Adduction of hip

Weak flexion of knee

Internal rotation of hip

Assists with flexion of hip



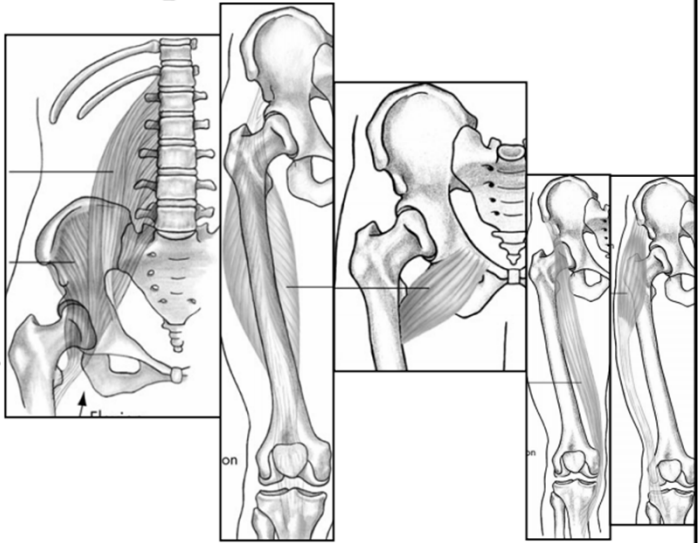
© 2007 McGraw-Hill Higher Education. All rights reserved.

9-58

Hip Flexion

- **Agonists**

- Psoas
- Iliacus (Iliopsoas)
- Rectus Femoris
- Pectineus
 - Sartorius
 - Tensor Fasciae Latae



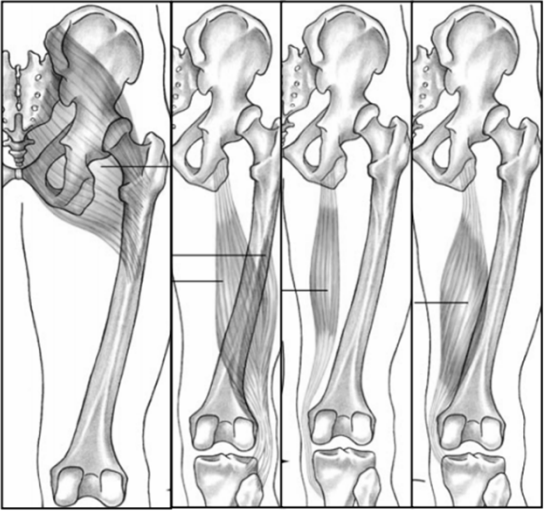
© 2007 McGraw-Hill Higher Education. All rights reserved.

9-59

Hip Extension

- **Agonists**

- Gluteus Maximus
- Biceps Femoris (Long Head)
- Semitendinosus
- Semimembranosus

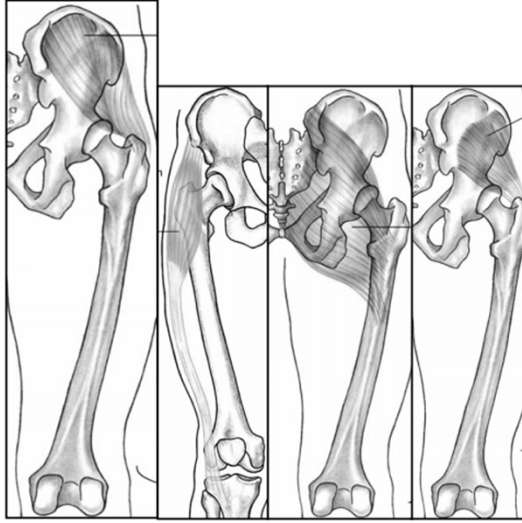


© 2007 McGraw-Hill Higher Education. All rights reserved.

9-60

Hip Abduction

- Agonists
 - Gluteus Medius
 - Tensor Fasciae Latae
 - Gluteus Maximus
 - Gluteus Minimus

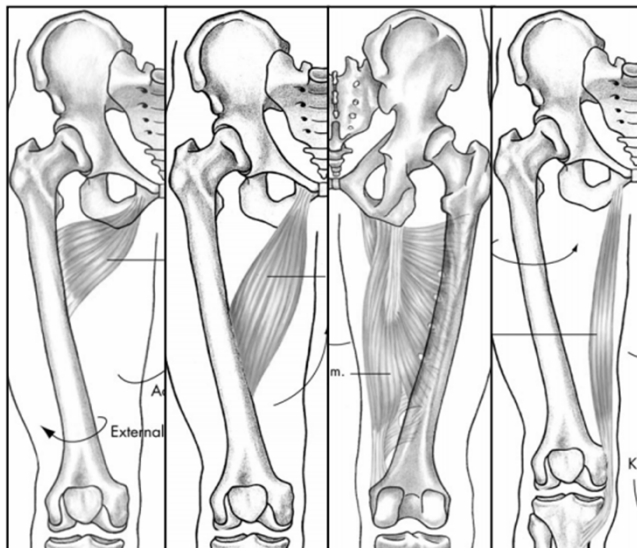


© 2007 McGraw-Hill Higher Education. All rights reserved.

9-61

Hip Adduction

- Agonists
 - Adductor Brevis
 - Adductor Longus
 - Adductor Magnus
 - Gracilis

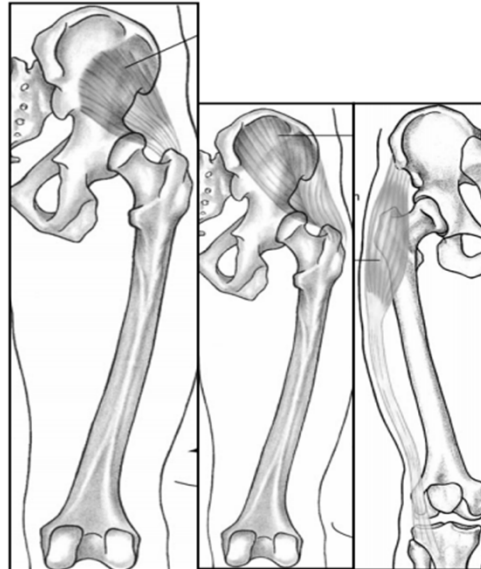


© 2007 McGraw-Hill Higher Education. All rights reserved.

9-62

Hip Internal Rotation

- **Agonists**
 - Gluteus Minimus
 - Gluteus Medius
 - Tensor Fasciae Latae

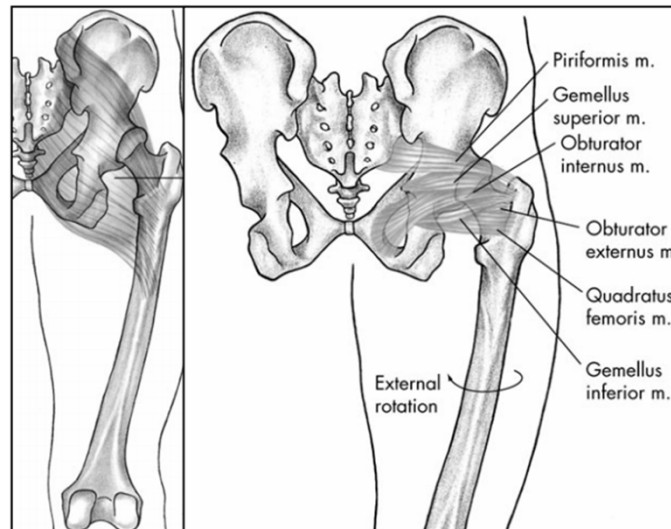


© 2007 McGraw-Hill Higher Education. All rights reserved.

9-63

Hip External Rotation

- **Agonists**
 - Gluteus Maximus
 - Six Deep External Rotators



© 2007 McGraw-Hill Higher Education. All rights reserved.

9-64